Journal of Physics:
Conference Series

PURPOSE-LED PUBLISHING™

PAPER • OPEN ACCESS

The use of raspberry pi as a portable medical image processing

To cite this article: C E Widodo *et al* 2020 *J. Phys.: Conf. Ser.* **1524** 012004

View the article online for updates and enhancements.

You may also like

- Multimodal optical microscopy system with Rheinberg and polarization modes of imaging on a portable Raspberry Pi platform for diverse applications
Biprav Chetry and Pabitra Nath

- Deep learning-based real-time detection and classification of tomato ripeness stages using YOLOv8 on raspberry Pi
Md Nahiduzzaman, Rusab Sarmun, Amith Khandakar et al.

- Implementation of vibration signals receiving unit on Raspberry single-board computers
V A Faerman, A V Tsavnin and S A Andreev

This content was downloaded from IP address 105.9.59.14 on 10/02/2026 at 18:49

The use of raspberry pi as a portable medical image processing

C E Widodo, K Adi, I Gunadi

Department of Physics, Faculty of Science and Mathematics Diponegoro University, Semarang Indonesia

Corresponding author: catur.ediwidodo@gmail.com

Abstract. This paper presents the image processing implementation in Raspberry Pi. Raspberry Pi is a system built-in and is a low-cost computer that can be used to reduce system complexity in real-time applications. For programming, it's very good to use Python. Raspberry pi has a Camera Slot Interface (CSI) to interface the camera with Raspberry Pi. Low contrast images captured using the Raspberry Pi camera module can be scaled up first to identify specific image regions. The most important processing is the removal of noise as a result of noise disturbance during image acquisition on the camera. Due to its small size, which is about the size of a credit card and its lightweight, raspberry pi is very suitable for use as a portable medical image processing system. Besides that Raspberry Pi also consumes low power.

1. Introduction

Image processing is a form of signal processing where the input is in the form of images and the output from image processing can be in the form of images or a set of characteristics or parameters associated with images. Digital image acquisition usually experiences undesired camera shake and due to unstable camera movements. Therefore an image enhancement algorithm is needed to eliminate this undesired camera shake. This image processing concept is implemented in Raspberry pi in the application of medical images.

Raspberry Pi is a built-in system that has the size of a credit card developed in the UK by the Raspberry Pi Foundation. Raspberry Pi is based on the Broadcom BCM2835 system on a chip (SOC) that includes a 700 MHz ARM1176JZF-S (ARM V6K) processor, Broadcom Video Core IV CPU processor which has 17 pins, 3.5W of power, and 512MB. RAM memory. The Raspberry Pi system has a Micro SD card reader socket for boot and storage media. This system provides the Debian Linux Raspbian operating system for download. Python is used as the main programming language for Raspberry Pi.

2. Methods

The proposed goal in this research is the use of Raspberry Pi as the main controller for a portable medical image processing system. After installing the Raspbian operating system and the Python programming language [1,2], all required hardware components are connected and the power supply is turned on. The system will boot and operate based on the Raspbian Operating System. The system than works on the Python software and checks the network settings to update the Python software with commands in the terminal window. The following packages must be installed to implement the proposed model. The packages are python-matplotlib, python-numpy, python-script and python-image library. Camera settings are activated to take pictures and save them in a folder. Python code is run to check the image processing algorithm. The proposed method implementation is shown in the flow chart in Figure 1.

Content from this work may be used under the terms of the Creative Commons Attribution 3.0 licence. Any further distribution of this work must maintain attribution to the author(s) and the title of the work, journal citation and DOI.
Published under licence by IOP Publishing Ltd

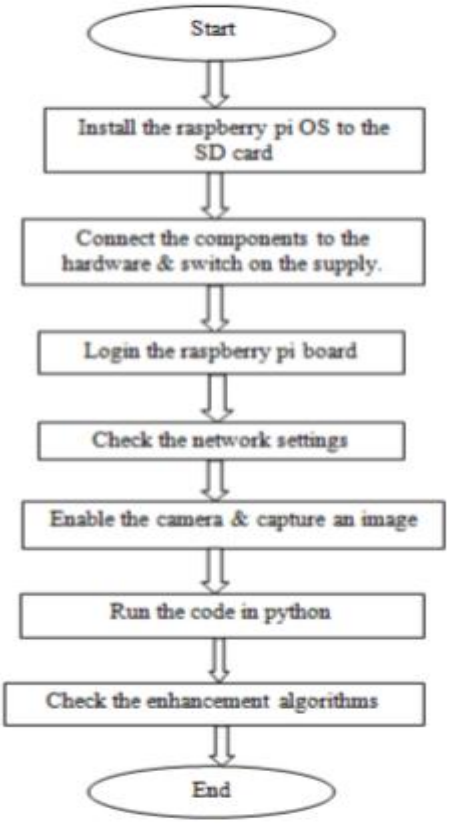

Figure 1.Flow chart of the method

3. Results and discussion

Our system is used to detect thorax images whether or not they have pleural effusion [3]. The pleura is a double layer of thin tissue consisting of mesothelial cells, connective tissue, capillaries, and lymph vessels [4,5]. The entire network separates the lungs from the chest wall and mediastinum. The pleura consists of visceral pleura and parietal pleura with a cavity containing a small amount of fluid as a function of the lubricant in breathing. Under normal circumstances, the chest X-ray can not be shown in the pleural layer. Abnormalities that are often found are fluid in the pleural cavity (pleural effusion), the air in the pleural cavity (pneumothorax), infection (pleuritis), and pleural tumor.

Pleural effusion occurs due to excessive accumulation of pleural fluid. Pleural fluid is found in the pleural cavity, which is the area between the lungs and the chest wall in the human body. Excessive formation of fluid in the pleural cavity can be caused by abnormalities in the lungs such as bacterial, viral, fungal infections, lung tumors, mediastinal tumors, and metastases. Other causes originate from diseases such as lymph, hypoproteinemia in the kidney, liver, and heart failure. Not infrequently caused also by accidental trauma or surgery.

On chest X-ray examination the pleural fluid appears as homogeneous cloaking covering the lower lung structure, which is usually relatively radiopaque with a concave upper surface, running from the upper lateral to the lower medial direction. Fluid fills the hemithorax space so that the beak tissue will be pushed toward the central / hilum, and sometimes pushing the mediastinum towards the contralateral. In the thoracic image, good irradiation results can be distinguished from normal lungs and effusion by looking at the lower lung. Normal lungs are more oblique compared to lungs identified by effusion.

The stages of image processing in this study are the determination of the region of interest (ROI), segmentation, measurement of the pleural slope and classification of whether the lung is normal or the lung is suffered from pleural effusion.

3.1 Determination of ROI

Normal thoracic image and thoracic image were identified pleural effusion in the form of digital images with JPG format carried out the process of determining ROI. The determination of ROI aims to focus the part of the image to be processed, namely the lower right pleural image. The determination of ROI is done by cutting the whole thoracic image into quarters by taking into account the ratio of the thoracic image. Figure 2. shows the result of determining ROI.

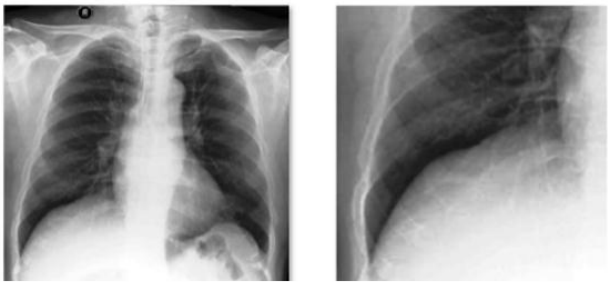

Figure 2. Result of determining ROI.

3.2 Segmentation

Then image segmentation is done using the thresholding method. Image segmentation aims to separate objects with background per segment. The output of the image segmentation process in the form of binary images. The threshold process is carried out by checking the gray degree value in the image and determining the threshold value. If the gray degree value is less than the threshold value then the pixel color turns black, and vice versa if the pixel is more than the threshold value then the pixel color will change to white. Figure 3 shows the results of thresholding segmentation.

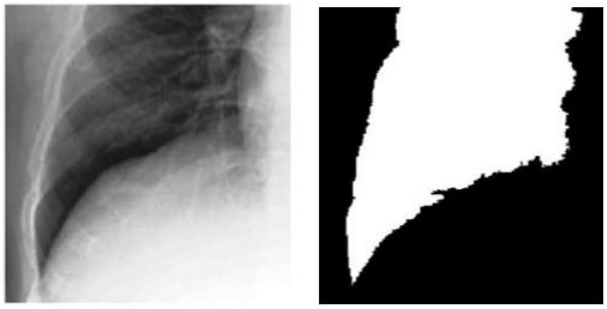

Figure 3. The results of segmentation

3.3 Determination of the Pleural Slope

Pleural slope determination is done by finding the distance between the center of the pleural image to the edge of the pleural image every 5 pixels. The distance between the center of the pleural image to the edge of the pleural image is referred to as the y-axis and the horizontal pixel distance of each 5 pixels is called the x-axis. The meeting of the x-axis and the y-axis will form points with x and y coordinates. Then the points are connected to form a line and then obtained a line gradient from the pleural image. Figure 4 shows the process of the pleural slope search.

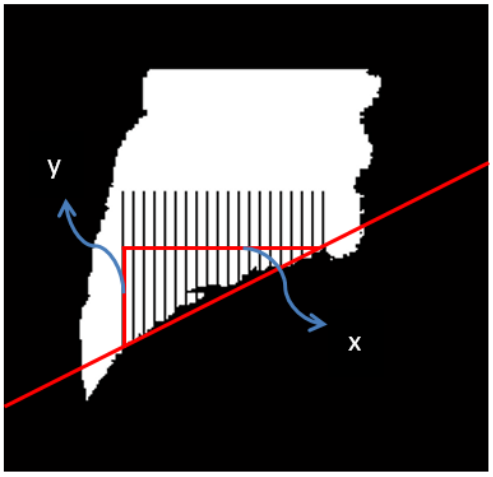

Figure 4. The process of pleural slope search

3.4 Classification

From the calculation of the pleural slope using 100 images shows that the normal pleural image gradient ranges from 0.36 to 0.79, while the pleural image gradient identified effusion ranges from 0.01 to 0.26. That is, the pleural slope in the normal lung is greater than the pleural slope in the lungs suffering from pleural effusion. The fundamental difference between a normal lung and a pleural effusion lung is that the lower end of the normal lung is more pointed than the lower end of the pleural effusion lung. This is due to the accumulation of fluid at the lower end of the lung of patients with pleural effusion so that the pleura is flatter than the normal lung. From calculations, it can be concluded if the pleural slope is greater than 0.31, then the lung is normal and if it is less than 0.31, then the lung is suffering from pleural effusion.

4. Conclusion

We can build a portable medical image processing system using Raspberry Pi hardware and a special camera for Raspberry Pi and Python and OpenCV software. Our system can classify the image of the lungs whether they are normal or suffer from pleural effusion. The system can do classification automatically and quickly. Besides that, the system that we made is concise, lightweight and easy to carry everywhere.

Acknowledgment

Financial assistance was provided by the Government of the Republic of Indonesia through the Faculty of Science and Mathematics of the Diponegoro University.

References

[1] Upton E and Halfacree G 2016 *Raspberry Pi User Guide 4 th Edition* John Willey & Sons West Sussex UK
[2] Monk S 2014 *Raspberry Pi Cook Book* O' Reilly Media Sebastopol California
[3] Blum R and Bresnahan C 2013 *Python Programming for Raspberry Pi in 24 Hours* SAMS Publishing Indiana USA
[4] Shilpashree K S, Lokesha H and Shiukumar H 2015 *IJARCCE* **4** (5)
[5] Cobo F, Granger J R, Sampedro 2017 *Revista Espanola de Quimioterapia* **30** (4)
[6] Vorster M J, Allwood B W, Diacon A H and Koegelenberg C F 2015 *Journal of Thoracic Disease* Vol. **7** (6)
[7] McGrath E E and Anderson P B 2011 *AJCC* **2** (2)